

## ULTRASONIC EXAMINATION OF THE TONGUE SHAPE CHANGES IN THE PROCESS OF ARTICULATION OF VOWELS

T. GUDRA, K. J. OPIELIŃSKI, T. SOBCZAK

Wrocław University of Technology  
Institute of Telecommunications, Teleinformatics and Acoustics  
Wybrzeże Wyspiańskiego 27, 50-370 Wrocław, Poland  
e-mail: tadeusz.gudra@pwr.wroc.pl

*(received June 15, 2006; accepted September 30, 2006)*

This paper presents results of ultrasonic examination of changes in tongue shape during the process of articulation of vowels by people (without pronunciation disorders). The position of the tongue while pronouncing a definite vowel and the influence of individual anatomical differences upon the tongue shape were examined. Results are presented as ultrasonograms obtained in the B- and TM-type presentations. The TM mode enables, among others, determining the amplitude of deflection of a point on the tongue surface during articulation that is the most change-prone at a given distance from the hyoid bone. Obtained results were used for design and construction of a tongue phantom and a mechanical setup to control the phantom shape. The proposed tongue phantom is crucial element of a natural tongue motions simulator during articulation that can be used as a major tool in therapy of deaf people, people with hearing and pronunciation disorders.

**Key words:** tongue shape changes, vowels articulation.

### 1. Introduction

Ultrasonic examinations are at present one of the most popular means of diagnosing the state of internal organs in medicine. The basic advantage of this kind of examinations is their non-invasive nature and the possibility of repeating them any number of times.

The ultrasonic examination can provide a vast amount of information on soft tissues. The aim of most ultrasonographic examinations in medicine is diagnosing the state of organs, inner organs or of the fetus and detecting possible defects in their functioning. This paper shows a different character of ultrasonic examinations, which is use during determining the specifics of the tongue shape and its changes of articulation definite speech sounds (vowels). The data obtained this way are the basis for elaborating a physical model consisting of a tongue phantom and a system to control its shape. To produce a tongue phantom it is necessary to know the basic anatomy and physiology of this organ.

In the paper [1–3] what was discussed was one of the possible methods of logopedic therapy of people with hearing disorders and pronunciation disorders. In this method the

main problem is the visual feedback between the person subjected to the therapy and a pattern of the tongue shape while articulating particular speech sounds. The way of doing articulation exercises shown in the paper [1] is the basic source and inspiration of this paper developing and modifying the content of the paper [1]. The specifics of such a therapy imply the projection of the physical model in several stages: the first stage encompasses ultrasonographic examinations of people articulating correctly definite speech sounds. The aim of these examinations is obtaining as much information on the tongue shape as possible as well as information on individual differences resulting from anatomical and morphological conditions of the speech organ. The next stage is defining possible differences between individuals and optimizing the outline of the tongue surface shape for a given speech sound. These data are the basis for producing and appropriate shaping of the artificial speech organ and its mechanical control in such a way that its upper shape represents the shape assumed as optimal on the basis of ultrasonographic examinations of people articulating correctly.

## 2. Anatomy and morphology of the tongue

The tongue (the Latin *lingua*) is an organ participating in speech sounds' articulation in the process of speaking. It consists of the dorsum and the base (root) (Fig. 1).

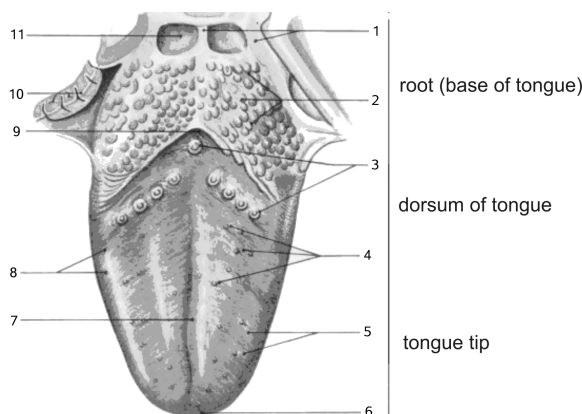


Fig. 1. Tongue: 1 – lateral and medial tongue-epiglottis folds, 2 – tongue tonsil, 3 – circumvallated papillae, 4 – fungiform papillae, 5 – filiform papillae, 6 – tongue's tip, 7 – tongue's medial groove, 8 – foliate papillae, 9 – blind aperture, 10 – palatal tonsil, 11 – epiglottis vallecula [4].

Most of the tongue is built of muscles divided into halves by the *Septum linguae*. The tongue muscles are divided into internal and external tongue muscles. The internal muscles enable a higher flexibility of the tongue and the outer muscles make it possible for the tongue to move backward and forward. The inner muscles are covered with the strong but flexible *Aponeurosis linguae*, separating the tongue mucous membrane from the muscle layer.

Special attention should be paid to the anatomy of the part called the tongue dorsum (Fig. 1) The mucous membrane in this part consists of the multilayer non-keratotic epithelium, typical of the throat cavity, firmly connected with the *Aponeurosis linguae* lying under the epithelium. On the bottom side of the tongue the mucous membrane is less firmly connected. The mucous membrane of the tongue dorsum shows small shifts called *Papillae linguales*, partly visible through a microscope. The shifts enable sensing tastes, and they do not occur on the tongue's other areas.

The most important goal while designing the tongue phantom is obtaining its desired flexibility and elasticity, maintaining the real proportions.

### 3. Visual feedback and its use in logopedia

Ultrasonography allows us to visualize the outline of the tongue surface and its muscle structure while resting and moving [5–7].

In the paper [1] the authors presented the possibility of using the ultrasonic examination of the tongue in phoniatric diagnosing and rehabilitation by visualizing the shapes of the tongue lateral surface while correctly articulating Polish vowels and during articulation exercises in the system of visual feedback in a child with correct hearing and in a deaf child. The methodology of this examination looks as follows. An ultrasonograph was used with a sector probe of 3.5 MHz and with a sector of  $100^\circ$ . The probe was placed as in Fig. 2.

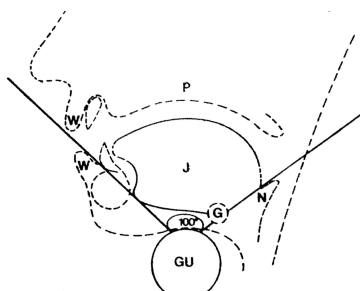


Fig. 2. Location of ultrasonic probe in examination of tongue position changes GU – ultrasonic probe, W – lip, J – tongue, P – palate, N – epiglottis, G – hyoid bone [1].

Using an ultrasonograph with the B-type presentation what was obtained was an image of the longitudinal cross-section and the outline of the surface from the shadow of the hyoid bone to the shadow of the teeth. The examinations of the tongue's lateral surface outline while correctly pronouncing Polish vowels were carried out in five people – in this way both static and moving (recorded as video freeze frames) pattern images were produced. Next the pattern images were used as the pattern for articulation exercises. Results were an incentive to further research on improving the efficiency of this methodology of exercises for people with hearing disorders.

#### 4. Examinations of the tongue shape changes in the process of vowels articulation by people articulating correctly

Within the scope of this paper the examinations were conducted on a setup consisting of the following devices:

- a Picker LS 2400 ultrasonograph equipped with a 5 MHz linear probe,
- a mechanism of shifting the probe to an assigned distance,
- a PC with a Dazzle DVC 150b video card enabling the acquisition and storage of the images from the ultrasonograph.

The probe was fixed with a screw in the mechanical setup for shifting with the accuracy of 0.1 mm. Then the probe was placed on the examined surface in two ways: in order to obtain longitudinal and transverse images.

The measurements were carried out in the form of type B and type TM imagings. The type B imaging provided information on the shape of the tongue's upper surface both in the longitudinal and the transverse cross-sections, depending on the distance from the point of reference that was the origin of the hyoid bone marking the observation boundary (observing through the bone tissue is not possible because of the high attenuation of the ultrasonic wave in this tissue and because of the examined person's discomfort, for whom the pressure on the bone would be very unpleasant). The presentation in the TM mode allowed us to determine the deflection amplitude of the point on the tongue surface, which is the most affected by the shifts, at a given distance from the hyoid bone. The changes of the shape of this surface were examined while pronouncing vowels: 'a', 'e', 'u', and fricatives 's', 'sz' in Polish. Voiced consonants were not examined because of their more complicated articulation the analysis of which (e.g. in the case of Polish 'r') requires recording each measurement for at least a few seconds (which is time-consuming and requires a vast computer memory). The measurement along the tongue was carried out for each articulated sound, whereas the measurement across the tongue was performed with a shift of the probe at every 2.5 mm from the shade of the hyoid bone up to the point at which the image on the ultrasonograph became too much interfered and/or unclear or till when the probe reached the point at which the tissue of the cranium rendered impossible the further observation of the tongue.

Figure 3 shows some examples of type B ultrasonograms of changes in the tongue upper edge shape while pronouncing the Polish vowel 'a'. Figure 4 shows the corresponding ultrasonograms in the TM presentation. The numbers of images in each series denote subsequently the starting point of measurements, and further measurements regard the subsequent shifts of the probe by 2.5 mm.

On each cross-section constituting the set of cross-sections determining type B presentation of changes of the tongue upper edge shape – the vertical axis and the horizontal axis are in units of centimetres. The horizontal axis:

- a) in the case of placing the probe across the tongue renders possible determining the width and the point of the tongue's largest deflections,
- b) in the case of placing the probe along the tongue renders possible determining the point of the biggest changes of the tongue shape in relation to the image's beginning that is assumed to be the shadow of the hyoid bone.

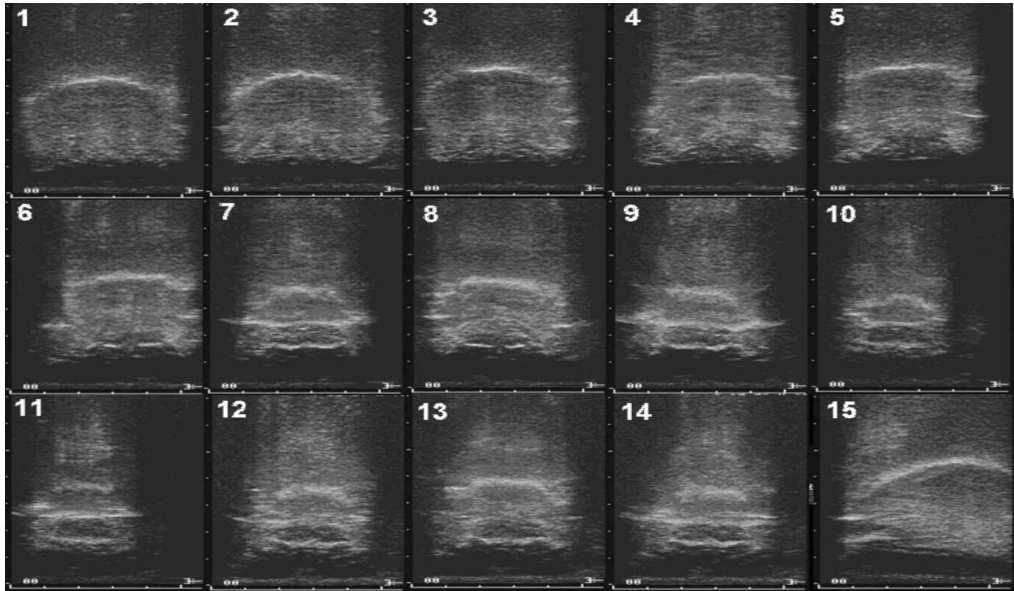


Fig. 3. Edge of tongue's upper surface while pronouncing 'a': images 1–14 obtained during shifts of probe by 2.5 mm from point zero that is edge of hyoid bone; image 15 shows edge of tongue's upper surface – view along tongue (left: shadow of teeth, right: shadow of hyoid bone).

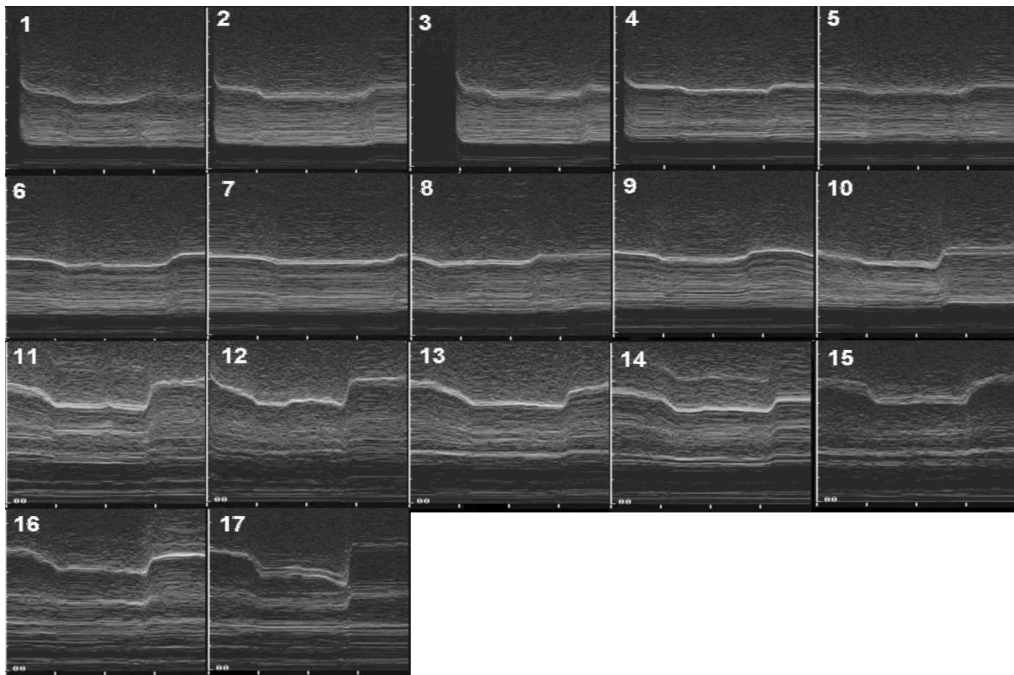


Fig. 4. Imaging tongue's movement in TM presentation while pronouncing Polish vowel 'a': images 1–17 obtained while shifting probe by 2.5 mm from point zero that is edge of hyoid bone.

The vertical axis determined the distance of a given point on the tongue's visible edge from the probe.

In the case of the TM-type presentation the horizontal axis is the time axis, and the vertical axis shows the deflection of the tongue edge at a given point assumed to be the point of the biggest changes of the tongue's position (it can be the tongue's deflection both upwards and downwards). This is most often a point situated on the tongue's axis.

### 5. Design of the setup for simulating the tongue shape changes in the process of articulating speech sounds

The designed physical setup for ultrasonic examination of changes in the tongue shape the process of speaking consists of:

- a) a tongue phantom,
- b) a mechanical setup controlled electronically for changing the phantom's shape,
- c) a setup for visualizing the registered phantom shape changes.

The schematic diagram of the connections between the particular parts of the setup is shown in Fig. 5.

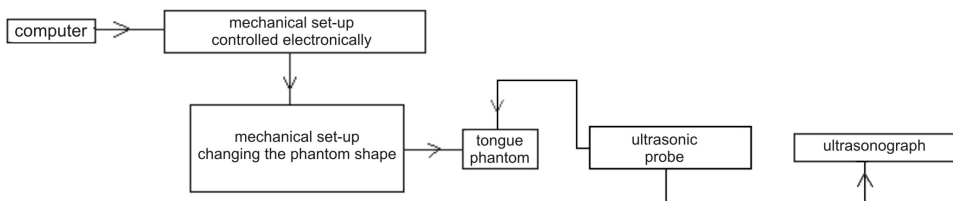


Fig. 5. Schematic diagram of setup for examining tongue shape changes.

The mechanical setup changing the tongue shape is electronically controlled by the software interface of the computer. Therefore it is necessary to write an application controlling the mechanical setup according to the parameters assigned by the user. Any changes of the phantom surface shape are received by the ultrasonic probe and visualized on an ultrasonograph as a presentation of B or TM type.




Fig. 6. Tongue phantom: a) side view, b) view from above.

Figure 6 shows the elaborated tongue phantom. Figure 7 shows a scheme of mechanical setup for shaping the tongue phantom.

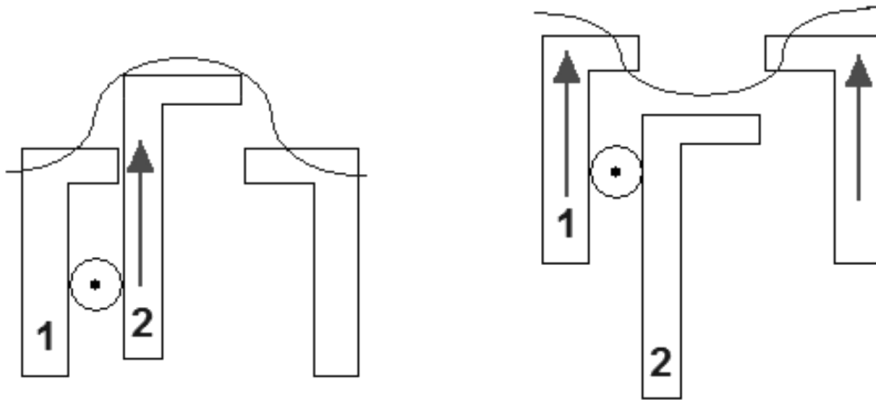


Fig. 7. Scheme of mechanical setup for shaping tongue phantom.

The setup elaborated according to the scheme shown in Fig. 5 allowed us to obtain images approximating those obtained during measurements for different people without pronunciation disorders. Figure 8 shows an example of a transverse cross-section of the tongue phantom obtained during articulating the Polish vowel 'a'.

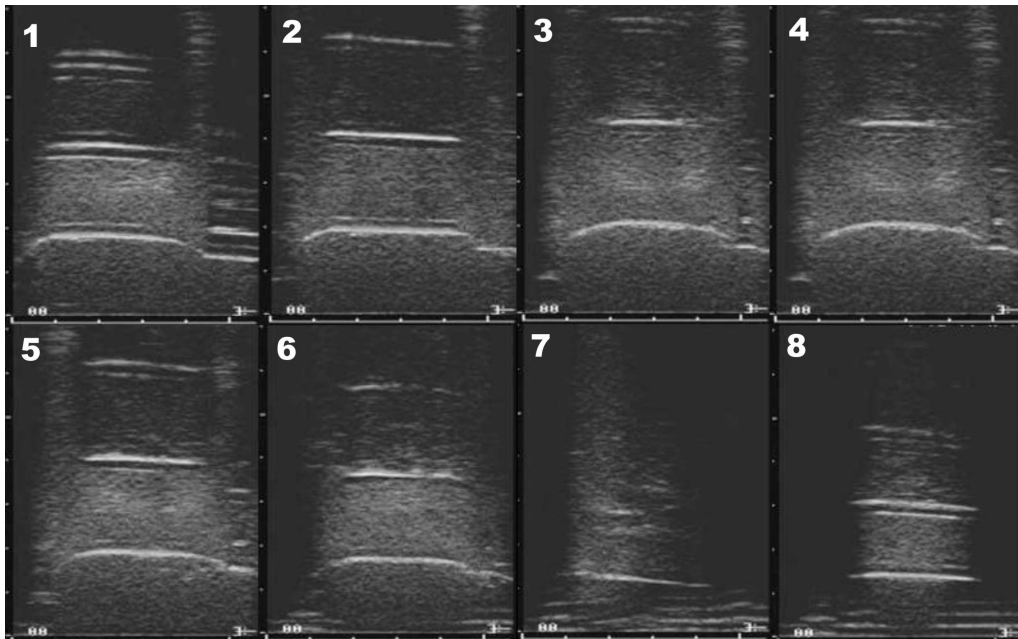


Fig. 8. Image of transverse cross-sections obtained while articulating vowel 'a': images 1–8 obtained while shifting probe by 5–10 mm from base of tongue phantom.

## 6. Conclusions

Ultrasonic examinations of articulation conducted with human subjects were limited to a few vowels and a few consonants, however the tests can also include syllables and words. A certain problem in ultrasonic determination of tongue cross-sections is the difficulty in situating the ultrasonic probe in such a way that an air layer between the particular sections of the tongue and a probe are eliminated. During articulation the tongue takes different shapes, and the oral cavity is filled with air. All air spaces between the contours of the tongue and other tissues in the oral cavity on the way of the ultrasonic beam render impossible a complete observation of the full length of the tongue, what was observed during experiments.

Using an artificial tongue as part of the setup with a visual feedback can have a positive effect on the patient following this specific pattern, due to the probability of learning how to articulate correctly increases.

The proposed physical setup for ultrasonic examination of the tongue shape changes in the process of speaking confirms the assumption that it is possible to construct a system representing the natural movement of the tongue while articulating speech sounds. Such a system can serve as a tool in the therapy of people with hearing disorders and speaking disorders.

## References

- [1] WEIN B., BÖCKLER R., KLAJMAN S., OBRĘBOWSKI A., *Ultrasonografia języka w rehabilitacji zaburzeń artykulacyjnych*, Otolaryngologia Polska, **45**, 133 (1991).
- [2] WEIN B., BÖCKLER R., KLAJMAN S., *Ultraschalluntersuchungen Der Aktiven Und Passiven Beweglichkeit Der Zunge*, Folia Phoniatica, **41** (1989).
- [3] KLAJMAN S., HUBER W., NEUMAN H., WEIN B., BÖCKLER R., *Ultrasonographische Unterstützung Der Artikulationsanbahnung Bei Gehörlosen Kindern*, Sprache-Stimme Gehör, **12**, 117 (1988).
- [4] [www.schmeh.de/anatomie](http://www.schmeh.de/anatomie)
- [5] STONE M., MORRISH K. A., SONIES B. C., SHAWKER T. H., *Tongue curvature: a model of shape during vowel production*, Folia Phoniatica, **39** (1987).
- [6] WEIN B., BÖCKLER R., HUBER W., KLAJMAN S., DÖRING W. H., *Ultrasound diagnosis in phoniatrics*, Proc. XV Congr. UEP, Erlangen 1988, G. Kittel, B. Schürenberg [Eds.], p. 50, 1988.
- [7] SHAKER T. H., SONIES B. C., HALL T. E., BAUM B. F., *Ultrasound analysis of tongue, hyoid and larynx activity during swallowing*, Invest. Radiol., **19**, 82 (1984).